

Impact of Rituximab in the Management of Pemphigus Vulgaris: A Case ReportMukesh Kumar Saphi^{1*}, Dr. Shiv Shankar Shah², Sunny Kumar Yadav¹, Yalla Sai Vijaya Durga¹¹Pharm.D Intern, Department of Pharmacy Practice, Aditya College of Pharmacy, Surampalem, Andhra Pradesh, India.²Research Scholar, AU College of Pharmaceutical Sciences, Andhra University, Andhra Pradesh, India.**ARTICLE INFO****Article History:****Received:** 22.08.2023**Revised:** 17.09.2023**Accepted:** 21.10.2023**Keywords :**

Auto-antibodies

Blisters

Desmosomes

Lesions

Pemphigus Vulgaris

Corresponding Author:**Mr. Mukesh Kumar Saphi,**

Pharm.D Intern,

Department of Pharmacy Practice,

Aditya College of Pharmacy,

Surampalem, Andhra Pradesh, India.

Email ID: rajakmukesh92814@gmail.com**ABSTRACT**

The term "Pemphigus" is derived from the Greek word Pempix means "bubble or blister" and Vulgaris means "common". It is a potentially life-threatening disease that causes erosions and blisters of the skin and mucous membranes. It is a chronic, rare, intra-epidermal bullous disease with a potentially fatal outcome and was originally named by Wickman in the years 1791. Pemphigus is an uncommon disease with an incidence rate ranging from 0.5 to 3.2 per 100,000 per year. In this article, we discussed a rare case report on the impact of Rituximab in the management of Pemphigus Vulgaris. The Inj. Rituximab was found to be more effective in treating Pemphigus Vulgaris along with supportive medication. By considering different literature, it has been concluded that Pemphigus Vulgaris has a relapse in nature. So, ongoing monitoring and adjustment of treatment are often necessary to manage the condition. Patient must require regular follow-up appointments with his healthcare professional to monitor the disease actively and adjust the treatment as necessary depending upon their clinical manifestations.

© 2023 Published by Universal Episteme Publications. This is an open access article under the CC BY license (<http://creativecommons.org/licenses/by/4.0/>)

Introduction

The term "Pemphigus" is derived from the Greek word Pempix means "bubble or blister" and Vulgaris means "common" [1]. It is a potentially life-threatening disease that causes erosions and blisters of the skin and mucous membranes [2]. It is a chronic, rare, intra-epidermal bullous disease with a potentially fatal outcome and was originally named by Wickman in the years 1791 [3]. Pemphigus is an uncommon disease with an incidence rate ranging from 0.5 to 3.2 per 100,000 per year. Men and women can be equally affected and most of the cases are occurring at the age of 50-60 years [4,5].

The immune system produces auto-antibody against the specific proteins of the desmosomal adhesion complex that leads to the intra-epidermal blister formation [6]. The progression of Pemphigus Vulgaris usually begins with painful persistent mucosal erosions most commonly in the mouth with many patients developing cutaneous manifestations [7, 8]. Pemphigus Vulgaris antibodies bind to keratinocyte desmosomes and to desmosome-free areas of the keratinocyte cell membrane [9,10].

It is mediated by circulating pathogenic auto-antibodies that attack the keratinocyte cell surface

proteins leading to acantholysis means the loss of intercellular connection between keratinocytes in the epidermal stratum spinosum that causes the intraepidermal clefts. If left untreated, PV is fatal due to the failure of the skin barrier that comes to a climax in fluid loss, electrolyte disturbances and causing opportunistic infection. The most common treatment method is the administration of oral corticosteroids and immunosuppressive agents and so far, there is still a lack of specific treatment for these diseases [11-13].

Case Report

A 35-year-old male patient was admitted to the department of DVL in a tertiary care hospital of Rajahmundry, Andhra Pradesh came with chief complaint of multiple crusted lesions on the abdomen, face, back region, lower and upper limb regions. Erosions over the back region (popliteal fossa) and scalp crushing were present with severe itching. On examination, it was found that the oral cavity also had a blister and sore on the mucosal membrane one month ago but now came for 2nd dose of Inj-Rituximab.

Observation

Under general physical examination, blood pressure was found to be 160/100 mmHg, pulse rate

100bpm, and temperature found to be afebrile. Systemic examination was found to be normal. Other specific tests like IIFS and ELISA were negative. The laboratory tests were found to be Hb-12.1gm/dl, PCV-37%, RBC-4.23million/cumm, Lymphocytes-20%, WBC-15,400 (leucocytosis), Platelets-2.25 lakhs, RBS-86 mg/dL and liver function tests were (SGOT-45 IU/L, SGPT-105 IU/L) elevated but the bilirubin level was normal.

Skin sample was taken from the blister for microscopic analysis and the report was found to be showing an intraepidermal vesicle with round separated keratinocytes (acantholytic cells) just above the basal layer of epidermis. Overall, based on clinical manifestations and laboratory and microscopic analysis (skin biopsy report) the patient was diagnosed with Pemphigus Vulgaris.

After confirmation of diagnosis, the standard treatment was started with Tab. Prednisolone 40mg/po/od (corticosteroid), Tab. Mycophenolate Mofetil 360mg/po/bd (immunosuppressant), Tab. Levofloxacin 500mg/po/od (antibiotics), Tab. Atarax 25 mg/bd (antihistamine), Tab. Fluconazole 150 mg once a week (antifungal).

After treatment, a significant improvement was observed in the patient's symptoms but new lesion formation was also observed so the patient was provided with an infusion of 1st dose of Inj. Rituximab 500 mg by monitoring closely. After that a significant improvement was seen in the patient and suggested for 2nd dose with regular follow-up appointments with the healthcare professional to monitor the aggravation and relapse of new lesions and adjust treatment as necessary depending upon their clinical manifestations.

Treatment Provided

After 15 days with regular follow-up and patient was admitted for 2nd dose of Inj. Rituximab that was given by monitoring all the vital parameters with pre-medication that includes Inj. Hydrocortisone 100 mg STAT, Inj. Pheniramine Maleate, 2cc STAT, Tab. Paracetamol 500mg STAT, Tab. Pantoprazole 40mg STAT after the Inj. Rituximab 500 mg dissolved in 50 ml given along with 450 ml normal saline (i.e by making 1mg/ml) was given slowly 2-3 ml/min of infusion intravenously. With the use of this therapy, a

significant improvement was observed as no new lesion was formed, the old lesion was healed (Fig no.2), the oral cavity was normal and the scalp crushing was reduced.

After 5 days of admission, a complete improvement was seen and the patient was discharged with Tab. Prednisolone 40mg/po/od, Tab. Mycophenolate Mofetil 360mg/po/bd, Tab. Levofloxacin 500mg/po/od, Tab. Hydroxyzine 25 mg/bd and suggested the appointments with his healthcare professional for follow up.

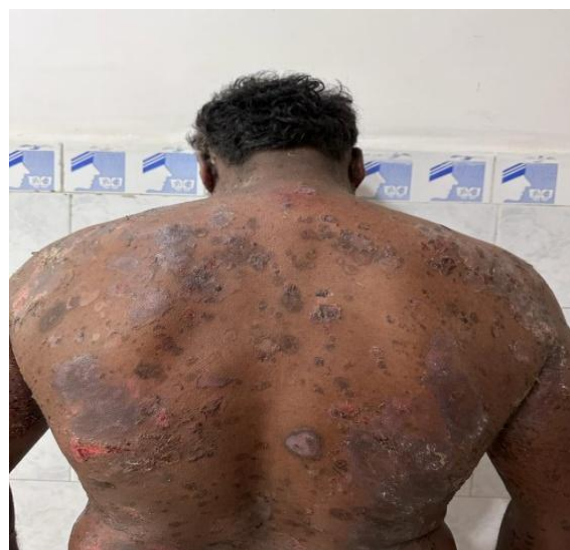

Figure 1: Condition of the skin after treatment with 1st dose of Inj. Rituximab

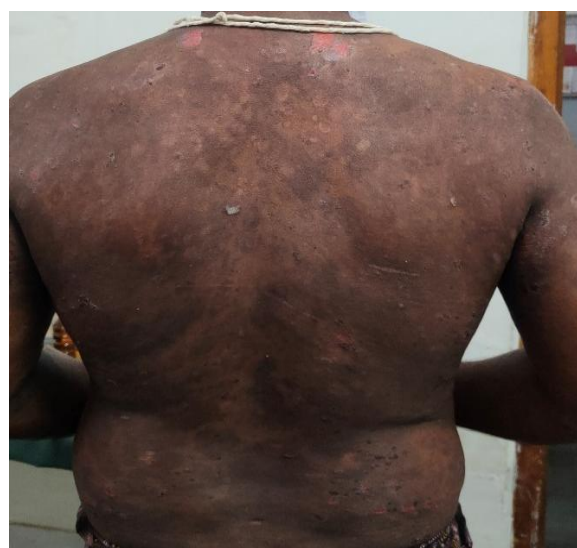

Figure 2: Condition of the skin after treatment with 2nd dose of Inj. Rituximab

Skin Biopsy Report

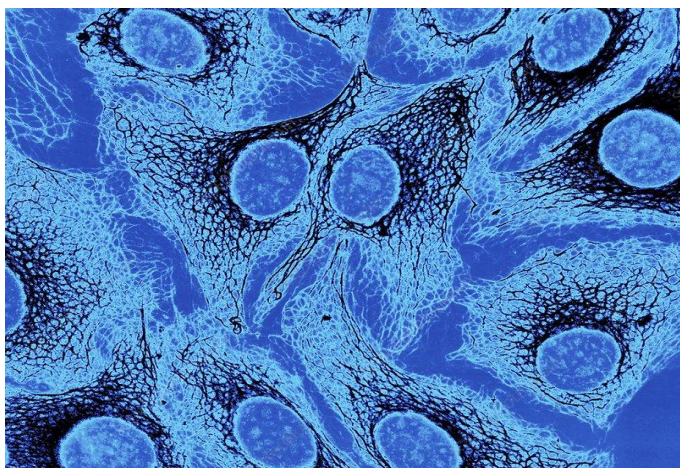


Figure 3: Round Keratinocyte under light microscopic

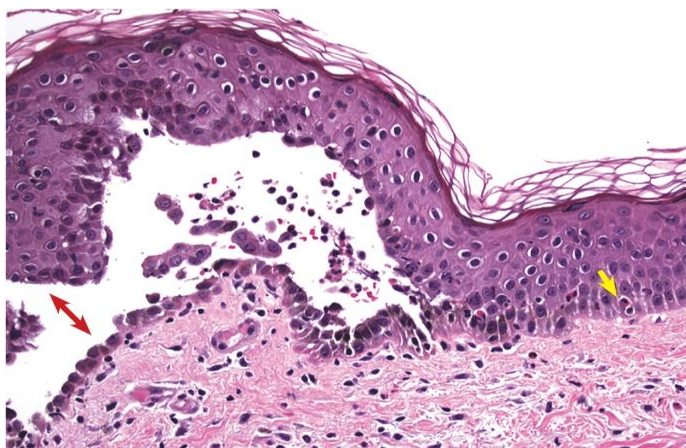


Figure 4: Rounded up and separated keratinocytes (Acantholytic cells)

Discussion

Pemphigus vulgaris (PV) is a vesiculobullous skin disease in that the immune system produces auto-antibody against the specific proteins of the desmosomal adhesion complex that leads to the intra-epidermal blister formation. The present case was a 35-year-old male patient who has a known history of pemphigus vulgaris and was under the treatment with Tab. Prednisolone (corticosteroid), Tab. Mycophenolate Mofetil (immunosuppressant), Tab. Levofloxacin (antibiotic), Tab. Hydroxyzine (antihistamine), Tab. Fluconazole (antifungal), antiseptic ointment, liquid paraffin and 1st dose of Rituximab. The patient came for 2nd dose of Rituximab which was given by continuous monitoring of vital parameters. After 2nd dose a significant improvement was observed with no new lesion formed, the old

lesion was healed (Figure: 2), the oral cavity was normal and the scalp crushing was reduced.

Conclusion

The Inj. Rituximab was found to be more effective in treating Pemphigus Vulgaris along with supportive medication. By considering different literature, it has been concluded that Pemphigus Vulgaris has a relapse in nature. So, ongoing monitoring and adjustment of treatment are often necessary to manage the condition. Patient must require regular follow-up appointments with his healthcare professional to monitor the disease actively and adjust the treatment as necessary depending upon their clinical manifestations.

Acknowledgment

The authors wish to acknowledge, Mr. Amit Kumar, Associate Professor of Aditya College of Pharmacy and also to the staff of GSL General Hospital, Rajahmundry for their valuable support.

Conflict of interest

All authors declare that no conflict of interest.

Informed Consent

Informed consent was taken from the patient

References

1. Shafer, Hine, Levy. Textbook of Oral Pathology 5th edition Neville, Damn, Allen, Bouquet. Textbook of Oral and Maxillofacial Pathology 2nd edition. Philadelphia 1995, saunders martin D Greenburg. Micheal Glick Burketts Orla medicine Diagnosis and treatment 10th edition.
2. Korman N. Pemphigus J. Am Acaddemat. 1998; 18; 1219-38.
3. Ahmed AR. Lymphocyte studies in Pemphigus. Arch Dermatol Res. 1998; 271: 111-5.
4. Pisanti S, Sharav Y, Kaufman E, Posner LN. Pemphigus vulgaris; the incidence in jews of different ethnic groups according to age sex and initial lesions. Oral path oral med. Oral Sug. 1974; 38(3); 382-7.
5. Vodo D, Sarig O, Sprecher E. The genetics of pemphigus Vulgaris. Front Med (Lausanne). 2018; 5: 226.

6. Melchionda V, Harman KE. Pemphigus vulgaris and pemphigus Foliaceus: an overview of the clinical presentation, investigations and management. *Clin Exp Dermatol.* 2019; 44(7):740-6.
7. Daltaban O, Ozcentik A, Akman Karakaş A, Ustun K, Hatipoglu M, Uzun S. Clinical presentation and diagnostic delay in pemphigus vulgaris: A prospective study from Turkey. *J Oral Pathol Med.* 2020; 49(7): 681-6.
8. Ali Y, Ali Reza, Gita F. Pemphigus vulgaris in Iran: Epidemiology and clinical profile. *SKIN med,* 2006; 5(2): 69-71.
9. Dagistan S, Goregen M, Miloglu, Çakur B. Oral pemphigus vulgaris: A case report with review of the literature, *Journal of Oral Science,* 2008; 50(3): 359-62.
10. Saito M, Stahley SN, Caughman CY, Mao X, Tucker DK, Payne AS, Amagai M, Kowalczyk AP. Signaling dependent and independent mechanisms in pemphigus vulgaris blister formation. *PLoS ONE.* 2012; 7: e50696.
11. Amagai M, Koch PJ, Nishikawa T, Stanley JR. Pemphigus vulgaris antigen (desmoglein 3) is localized in the lower epidermis, the site of blister formation in patients. *J. Investig. Dermatol.* 1996; 106: 351-5.
12. Amagai M, Tsunoda K, Zillikens D, Nagai T, Nishikawa T. The clinical phenotype of pemphigus is defined by the anti-desmoglein autoantibody profile. *J. Am. Acad. Dermatol.* 1999; 40: 167-70.
13. Karpati S, Amagai M, Prussick R, Cehrs K, Stanley JR. Pemphigus vulgaris antigen, a desmoglein type of cadherin, is localized within keratinocyte desmosomes. *J. Cell Biol.* 1993; 122: 409-15.

